

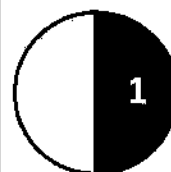
Question:

Total marks:

A 3rd gravida, 2nd para, pregnant 32 wks, presenting by mild attack of vaginal bleeding. On examination, the patient is hemodynamically stable, uterus lax, baby is cephalic, its back on the right side near midline, and FHS is 142 beats/min. & regular.

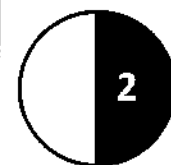
A- What is the provisional diagnosis?

-
-



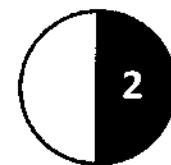
B- Explain your diagnosis

-
-
-



C- Suggest 2 subsequent steps for definite diagnosis.

1.
2.



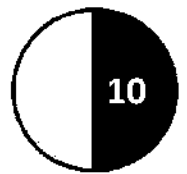
D- Put the proper treatment plan for this case?

-
-
-
-
-



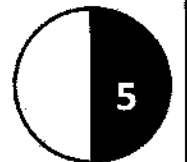
Question:

Total marks:



A- Tabulate the 5 differences between partial and complete vesicular mole.

	partial vesicular mole	complete vesicular mole.
Incidence		
Presence of fetal parts		
USS		
Chromosomal patterns		
Line of treatment		



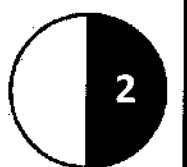
B- What is treatment of choice for complete vesicular mole?

.....

.....

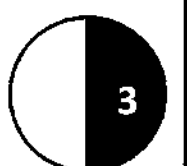
.....

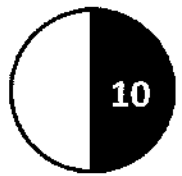
.....



C- Mention 3 methods of follow up measurers after its initial treatment.

1.
2.
3.

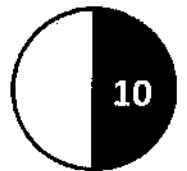




Question:

Total marks:

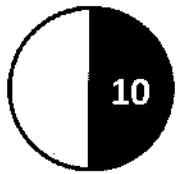
<p>A- Define the four stages of normal labor?</p> <p>1.</p> <p>2.</p> <p>3.</p> <p>4.</p>	
<p>B- Mention 6 essential steps to conduct the second stage of normal labor.</p> <p>1.</p> <p>2.</p> <p>3.</p> <p>4.</p> <p>5.</p> <p>6.</p>	



Question:

Total marks:

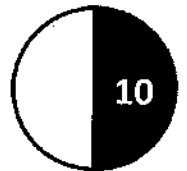
<p>A- Identify four prerequisites for vacuum extraction & explain why for each</p> <p>1.</p> <p>2.</p> <p>3.</p> <p>4.</p>	
<p>B- Mention 3 indications for the use of vacuum extraction.</p> <p>1.</p> <p>2.</p> <p>3.</p>	
<p>C- Mention 3 complication (fetal or maternal) for the use of vacuum extraction</p> <p>1.</p> <p>2.</p> <p>3.</p>	



Question:

Total marks:

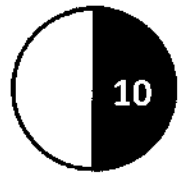
<p>A- List the items of Apgar scoring and define each</p> <ol style="list-style-type: none"> 1. 2. 3. 4. 5. 	
<p>B- Mention 5 measures for the management neonatal asphyxia.</p> <ol style="list-style-type: none"> 1. 2. 3. 4. 5. 	



Question :

Total marks:

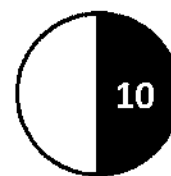
<p>A- What is the microbial etiology of PID, mention 4 types</p> <p>1.</p> <p>2.</p> <p>3.</p> <p>4.</p>	
<p>B- Mention 3 methods of the diagnosis of PID.</p> <p>1.</p> <p>2.</p> <p>3.</p>	
<p>C- Mention in details 5 lines for the treatment of PID</p> <p>1.</p> <p>2.</p> <p>3.</p> <p>4.</p> <p>5.</p>	



Question:

Total marks:

<p>A- List 6 of the WHO medical eligibility criteria for copper bearing IUDs</p> <p>1.</p> <p>2.</p> <p>3.</p> <p>4.</p> <p>5.</p> <p>6.</p>	
<p>B- Mention 2 absolute contraindications of the use of IUDs</p> <p>1.</p> <p>2.</p>	
<p>C- Recommend 3 suitable contraceptive methods for a lactating lady & explain why it is suitable?</p> <p>1.</p> <p>2.</p> <p>3.</p>	



Question:

Total marks:

<p>A- Describe the naked eye pathology of adenomyosis.</p> <p>.....</p> <p>.....</p>	
<p>B- Describe the microscopic appearance of adenomyosis</p> <p>.....</p> <p>.....</p>	
<p>C- Mention (5) clinical presentation of adenomyosis .</p> <p>1.</p> <p>2.</p> <p>3.</p> <p>4.</p> <p>5.</p>	