Peripheral Arterial Aneurysms

BY
MOHAMAD SHOKRY ABD ELGAWAD
LECTURER OF VASCULAR SURGERY
FACULTY OF MEDICINE
MANSOURA UNIVERSITY

- Arterial aneurysm was clearly identified (2000 BC) in the Ebers Papyrus, recommending, “Treat it with a knife and burn it with a fire so that it bleeds not too much.”

Definition

Aneurysm: irreversible permanent localized dilatation of the artery by more than 50% percent compared with the expected normal diameter of the artery due to mural weakness and hemodynamic forces affecting the wall.

Ectasia :Widening of an artery of less than fifty percent of its normal diameter.

Arteriomegaly : diffuse dilatations and tortuosity of multiple arterial segments often, greater than fifty percent of the expected diameter.

As regard the “peripheral artery aneurysm” excludes aortic, aorto-iliac, coronary and cerebral arteries.

Aetiology

- Degenerative causes
- Connective tissue diseases
- Trauma
- Inflammatory
- Congenital

Aetiology

- **Most aneurysms** are caused by degenerative disease affecting the vessel (atherosclerosis)
- **Structural weakness & Haemodynamic forces**
  - Damage to, and loss of intima
  - Reduction in the elastin and collagen content of the media
  - Collagen; tensile strength, adventitia
  - Elastin; recoil capacity, media
- **Risk factors**
  - smoking, hypertension, hypercholesterolaemia

Aetiology

- **Laplace's low**

  (Tension varies directly with radius when pressure is constant)

  - For every increase in the radius there is a large increase in tension, leading to further enlargement of the aneurysm

Aetiology

- **Congenital**

  Marfan's syndrome
- **Post-stenotic**

  Coarctation of the aorta, Cervical rib, Popliteal artery entrapment syndrome
- **Traumatic**

  Gunshot, stab wounds, arterial punctures
- **Connective tissue diseases**

  Takayaso's disease, Behcet's disease

Aetiology

- **Mycotic**

  Bacterial endocarditis, syphilis
- **Pregnancy associated**

  Splenic, cerebral, aortic, renal, iliac & coronary

Classification

Pseudoaneurysms : haematoma derived from avessel, and enveloped by incomplete elements of the vessel wall, adjacent stroma, and fibrous tissue.

True aneurysms : include all the layers of the vessel

Classification

- **Fusiform**
  - Spindle-shaped involving whole circumference
- **Saccular**
  - Small segment of wall ballooning due to localized weakness

Presentation

- Pulsatile mass
- Incidental finding
- Embolism with distal arterial occlusion
- Compression of local structures may result in pain – edema
- Rupture

Diagnosis

- The main step in diagnosis is **clinical examination** by the physician ,find a pulsatile mass on palpation of the site of the mass that can be misdiagnosed.
- The confirmation of diagnosis can be done by **dupplex ultrasonography.**
- **a computed tomography and Angiography** scan should be retained for assessment of local operability, inflow, and distal runoff

Aneurysms in the arteries of the Lower extremity

Popliteal Aneurysm

- Is commonest (70%)
- 65% bilateral with 25% associated with AAA
- Etiology related to chronic flexion/extension
- Associated aneurysms – other leg, femoral, aortic

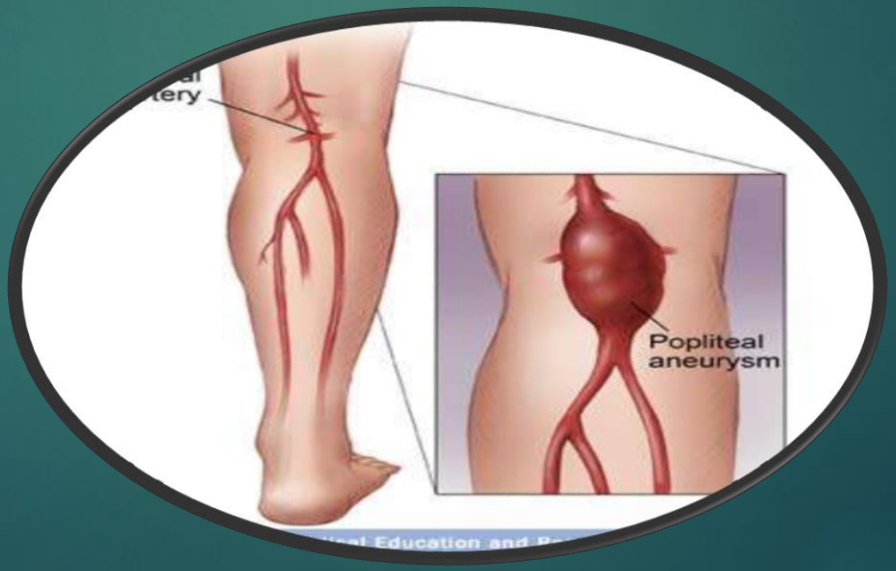

Symptoms of Popliteal Aneurysms

Many popliteal aneurysms have no symptoms. Common symptoms include:

- Pain behind the knee
- An edema (collection of watery fluid) in the lower leg
- Foot pain
- Ulcers on the skin of the feet that don't heal

Treatment

- Repair with arterial graft using PTFE,dacron,autogenous
- ENDOLUMINAL STENTING

Femoral Aneurysm

- TRUE aneurysm- Non specific etiology
- FALSE aneurysm anastomotic/traumatic

  catheter-induced/infected
- ***TYPE 1*** – Limited to Common Femoral Artery
- ***TYPE 2*** – Involving orifice of Profunda Femoris artery

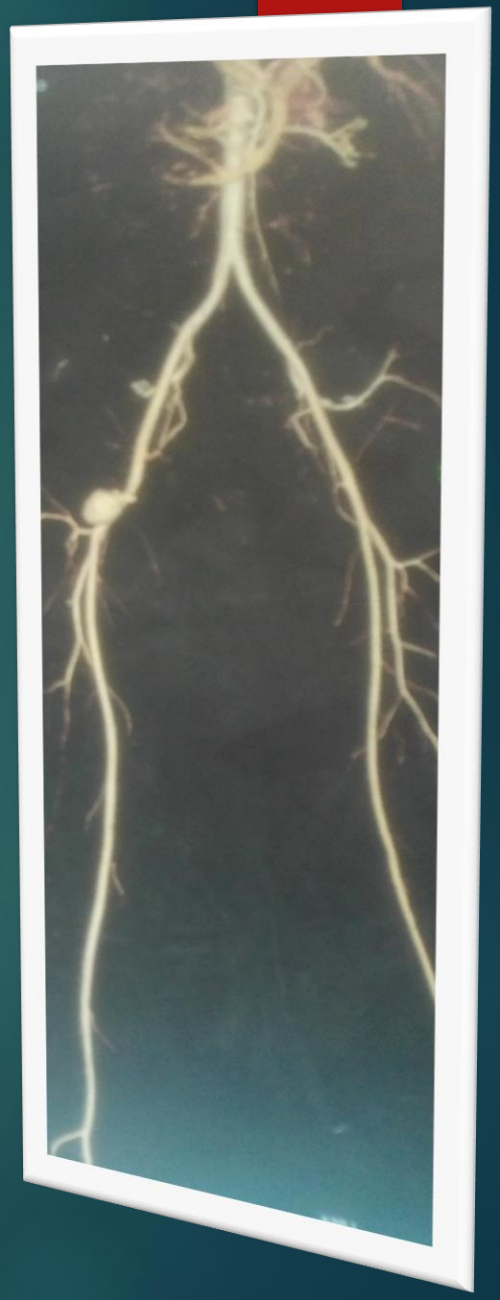

- Asymptommatic with pulsatile mass
- Local pain – pressure on ajacent nerve
- Limb edema/venous distention-venous compression
- Lower extremity ischemia with intermittent claudication/rest pain/gangrene
- COMPLICATIONS – THROMBOSIS -RUPTURE -EMBOLIZATION

OPERATIVE MANAGEMENT

TYPE 1 ANEURYSM

- INTERPOSITION GRAFT OF DACRON
- e PTFE

TYPE 2 ANEURYSM

- INTERPOSITION GRAFT TO SFA/ PFA with reimplantation of the other artery.
- SYNDACTYLIZATION- Suturing of Superficial and Profunda femoris arteries together to form a common lumen

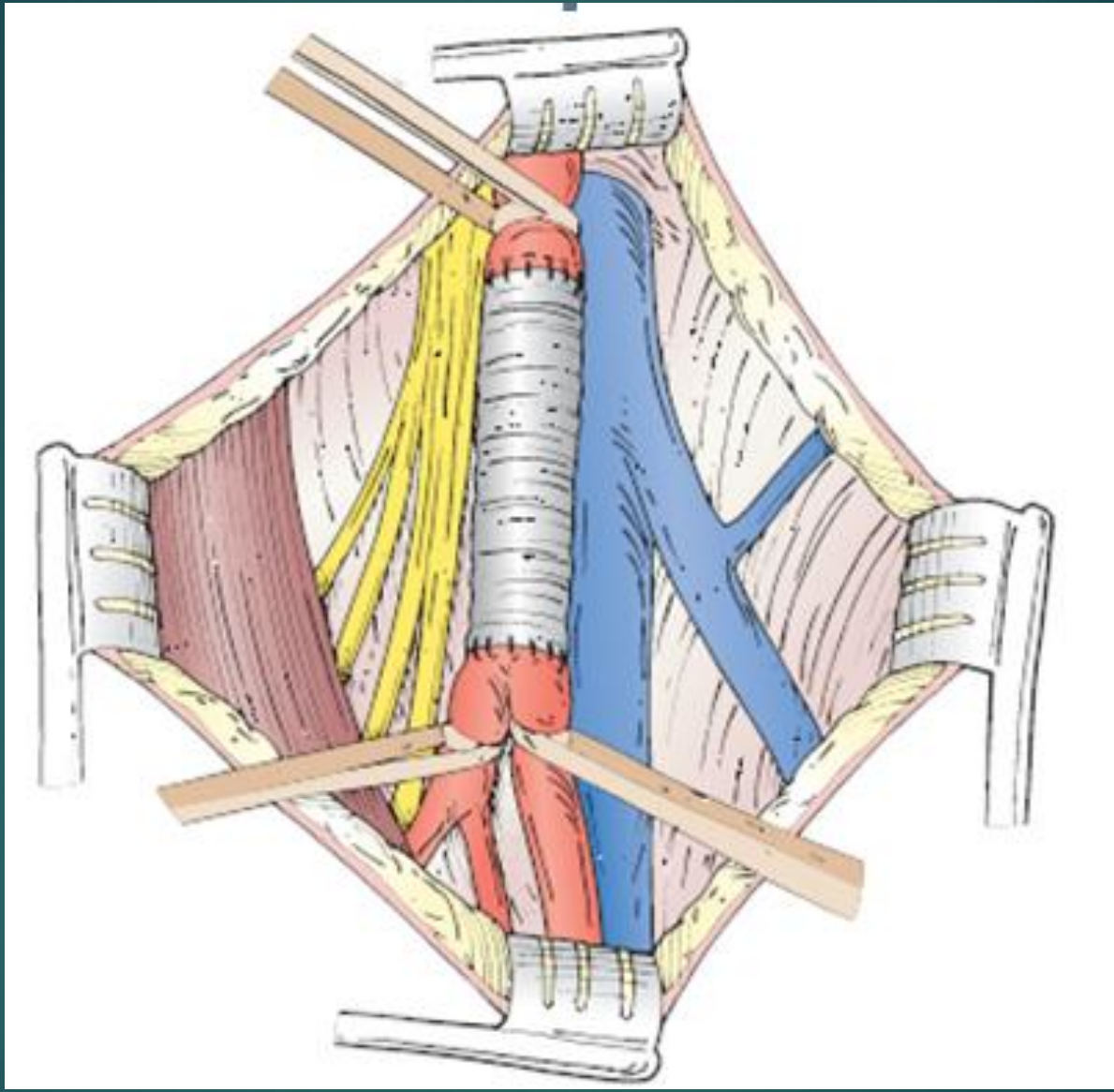

Bilateral CFA pseudoaneurysms in Behcet`s disase patient

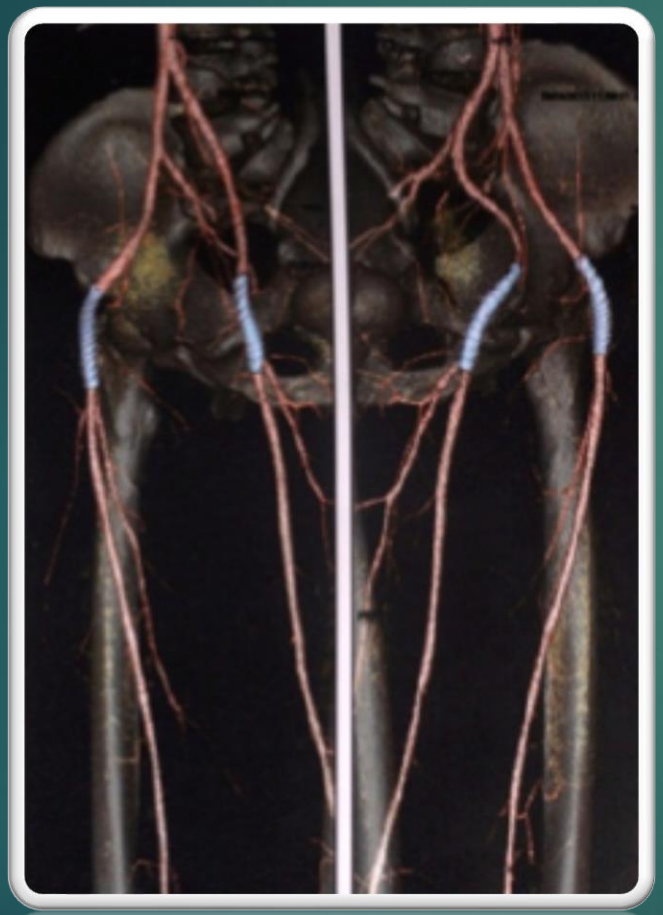

Aneurysms in the arteries of the upper extremity

Subclavian Aneurysm

Causes

- Atherosclerosis
- TOS
- Trauma
- Collagen vascular disease

Symptoms of Subclavian Aneurysms

- A pulsating mass above or below the collarbone
- Difficulty swallowing
- Difficulty breathing
- Chest pain
- A feeling of hoarseness in the throat
- Fatigue in the upper extremities
- Numbness, tingling, fatigue or ulcers in the fingers

SUBCLAVIAN- AXILLARY ANEURYSM

- POST STENOTIC DILATATION--- OUTLET OBSTRUCTION
- Younger patients/females/ right side more common
- Associated with CERVICAL RIBS
- Associated with Raynauds phenomenon.
- ARTERIOGRAPHY – To assess the degree of post stenotic dilation of the subclavian artery.
- Ttt : significant dilation– CERVICAL RIB removal , vascular reconstruction– mobilization with end to end anastomosis with or without short interposition vein or prosthetic graft.

ABERRANT RIGHT SUBCLAVIAN ARTERY

- Most common congenital abnormality of aortic arch
- Dysphagia lusoria– esophagus compressed against postr. Trachea
- Rx – propensity to cause symptom and lethal rupture

↓

RESECTION OF ANEURYSMAL ARTERY

WITH VASCULAR RECONSTRUCTION or

Stent grafts

HYPOTHENAR HAMMER SYNDROME

- Seen in men younger than 50 years age.
- ULNAR artery and nerve
- TRAUMA – MURAL degeneration : damage to Intima– THROMBOSIS, damage to MEDIA– TRUE ANEURYSM
- C/f– pain,cold sensation,paresthesias,cyanosis and mottling of digits, 4th and 5th digit involved

- THUMB not involved– RADIAL BLOOD supply
- RAYNAUD'S PHENOMENON- not seen
- surgical therapy

  -- cervicodorsal sympathectomy

  -- excision of ulnar artery aneurysm with ligation of ulnar artery and aneurysmectomy with microsurgical reconstruction of ulnar artery by reanastomosis or interposition vein graft.

Extracranial Carotid Artery Aneurysm

Symptoms

Extracranial carotid artery aneurysms don't always trigger symptoms. But if they get large enough, you can have:

- Difficulty swallowing
- Facial swelling
- A hoarse voice
- If a blood clot breaks away from an extracranial carotid artery aneurysm, it can cause a stroke or a transient ischemic attack (TIA), a mini-stroke that temporarily stops blood from reaching brain.

Diagnosis

- Angiography
- CT scan (computed tomography)
- Echocardiography (ultrasound testing)
- MRI (magnetic resonance imaging)

Treatment

- Medications to lower your blood pressure and cholesterol levels or to dissolve clots
- Monitoring every six months, if aneurysm is small
- Surgery or endovascular stent grafting

Splanchnic Artery Aneurysms

Elective intervention is required for all symptomatic aneurysms and for most aneurysms larger than 2 cm in diameter to reduce the risk of rupture and hence mortality

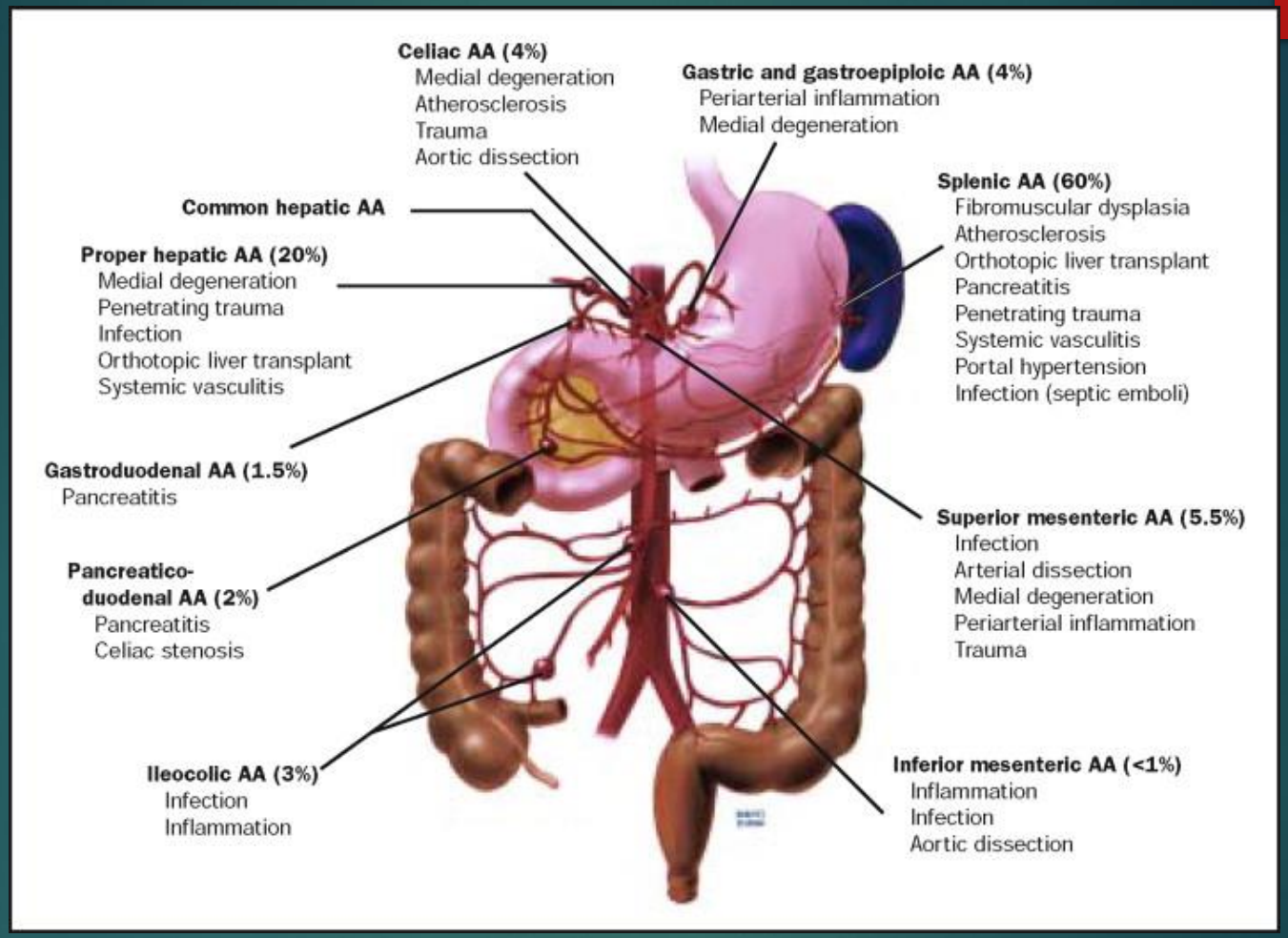
Celiac AA (4%)
Medial degeneration
Atherosclerosis
Trauma
Aortic dissection
Gastric and gastroepiploic AA (4%)
Periarterial inflammation
Medial degeneration
Common hepatic AA
Splenic AA (60%)
Fibromuscular dysplasia
Atherosclerosis
Orthotopic liver transplant
Pancreatitis
Penetrating trauma
Systemic vasculitis
Portal hypertension
Infection (septic emboli)
Proper hepatic AA (20%)
Medial degeneration
Penetrating trauma
Infection
Orthotopic liver transplant
Systemic vasculitis
Gastroduodenal AA (1.5%)
Pancreatitis
Superior mesenteric AA (5.5%)
Infection
Arterial dissection
Medial degeneration
Periarterial inflammation
Trauma
Pancreatico-duodenal AA (2%)
Pancreatitis
Celiac stenosis
Ileocolic AA (3%)
Infection
Inflammation
Inferior mesenteric AA (<1%)
Inflammation
Infection
Aortic dissection

SPLANCHNIC ANEURYSM

- 22 % present as clinical emergencies
- high resolution CT, MRA,USG-more recognition
- SPLENIC ARTERY ANEURYSM -- 60 %
- HEPATIC ARTERY ANEURYSM -- 20 %
- SUPERIOR MESENTRIC ARTERY -- 5.5%
- CELIAC ARTERY ANEURYSM -- 4%
- GASTRIC/GASTROEPIPLOIC -- 4%
- INTESTINAL -- 3%
- PANCREATIC -- 2%
- GASTRODUODENAL -- 1.5%

Celiac Artery Aneurysms

- **Etiology**

arteriosclerosis and medial degeneration. Trauma, dissection, and Takayasu arteritis are other causes. Syphilitic aneurysms are now uncommon

- **Clinical Manifestations**

1. initially by epigastric pain or upper gastrointestinal hemorrhage.
2. Worsening abdominal pain usually indicates a rapidly expanding aneurysm or rupture.
3. Dysphagia may occur from esophageal compression.
4. In earlier reports, nearly 80% of celiac artery aneurysms had ruptured by the time the patient presented

Management

- celiac ligation.
- aortohepatic bypass or direct aortic reimplantation.
- prosthetic grafts have a lower risk of occlusion than saphenous vein grafts.
- percutaneous transcatheter embolization.


LAT

Splenic Artery Aneurysms

Etiology and Pathogenesis

- 72% true aneurysms. 20 % have multiple aneurysms. Pancreatitis results in pseudoaneurysm.
- Saccular and at a bifurcation in the splenic hilum.
- Most common causes are arteriosclerosis and portal hypertension
- Less common causes include idiopathic dissection, septic emboli, polyarteritis nodosa, systemic lupus erythematosis, Ehlers-Danlos syndrome, fibromuscular dysplasia.
- Dilatation of the splenic artery resulting from increased blood flow during pregnancy likely predisposes to aneurysm formation. Similarly, increased splenic blood flow is considered the cause of splenic artery aneurysms in portal hypertension and after liver transplantation.

Clinical Manifestations.

- Left upper quadrant or epigastric pain that radiates to the left shoulder.
- Rupture of the aneurysm, which may manifest as hypovolemic shock, occurs in less than 2% of patients.
- The risk of rupture is much higher for pregnant women and for aneurysms larger than 2 cm in diameter.
- More than 95% of aneurysms in pregnant women are diagnosed after rupture[6] and are associated with a 75% maternal and 95% fetal mortality rate.
- the *double-rupture phenomenon*
- Arteriovenous fistula formation is a rare complication that leads to portal hypertension causeing small-bowel ischemia, the "mesenteric steal syndrome."

- Rupture of the aneurysm into the lesser sac is manifested initially as upper abdominal pain, but the patient is hemodynamically stable as long as bleeding is confined to the lesser sac. When blood overflows into the greater intraperitoneal sac through the foramen of Winslow, diffuse abdominal pain and hypovolemic shock develop. This is termed the ***double-rupture phenomenon***
- It has been suggested that the period in which bleeding is localized in the lesser sac allows time for surgical intervention in about 25% of patients.

Management

- Ruptured aneurysms of the splenic artery treated with **splenectomy**.
- A symptomatic or any diameter in a pregnant woman or a woman of childbearing age is considered to be an **absolute indication for elective repair.**
- An aneurysm **larger than 2 cm** is an indication for surgery
- An aneurysm **between 1 and 2 cm** in should be monitored closely with imaging every 6 months.
- Transcatheter embolization may be performed for all splenic artery aneurysms, except those located at the splenic hilum.
- Aneurysms of **the proximal splenic artery** can be treated with simple ligation, but those involving **the hilum** require splenectomy.
- **Aneurysmectomy** with end-to-end anastomosis is recommended for mid splenic aneurysms in a tortuous and redundant artery.
- In the presence of portal hypertension, transcatheter embolization or stent-graft placement may be preferred because the extensive collateral circulation that develops as a result of portal hypertension makes surgery more difficult.

- Although **conservative management** of splenic artery pseudoaneurysms has produced excellent results according to some reports, intervention in all cases irrespective of size or symptoms., failure does occur, especially when the pseudoaneurysm is associated with a pseudocyst of the pancreas.
- **Splenectomy, with or without distal pancreatectomy** is the current standard of treatment, with no reports of failure.


H
LAO/RAO
CRAN/CAUD
Name:LAU WENDY JANE***
ID:CT115997-08SS
DoB:25/05/1965
Date:24/11/2008
Time:10:26:28
No.:1
x 1.34
Inst:ST.Teresa's Hospital
Model:Sensation Cardiac 64
1
SOMATOM Definition Flash
12/2/2014
12:01:00
CT
R
R
Spin: 0
Tilt: 0
A
kV 120
mA 273-412
SL 0.75
SP 0.50
PX 0.83
512x512x769 [12 bit]
B 25 W
O 50 C
F
AcqNo:7
SL:
ST:188.00
CS:
TI:
kV:120.00
mA:
CM:APPLIED
GT:0.00
ImC:
W : 00334

Hepatic Artery Aneurysms

Etiology

- Almost 50% of hepatic artery aneurysms are pseudoaneurysms.
- Arteriosclerosis and acquired medial degeneration. Mycotic aneurysms are rare
- Other causes include polyarteritis nodosa, pancreatitis, liver transplantation, neurofibromatosis, Wegener granulomatosis, and tuberculosis.

Clinical Manifestations

- Right upper quadrant abdominal pain that radiates to the back.
- Rupture into the peritoneal cavity and manifest as abdominal pain with hypovolemic shock.
- Gastrointestinal hemorrhage may occur from erosion of the aneurysm into the stomach or duodenum.
- Erosion into the biliary tract occurs in nearly 50% of patients with rupture of a hepatic artery aneurysm the classic triad of biliary colic, hemobilia, and obstructive jaundice.

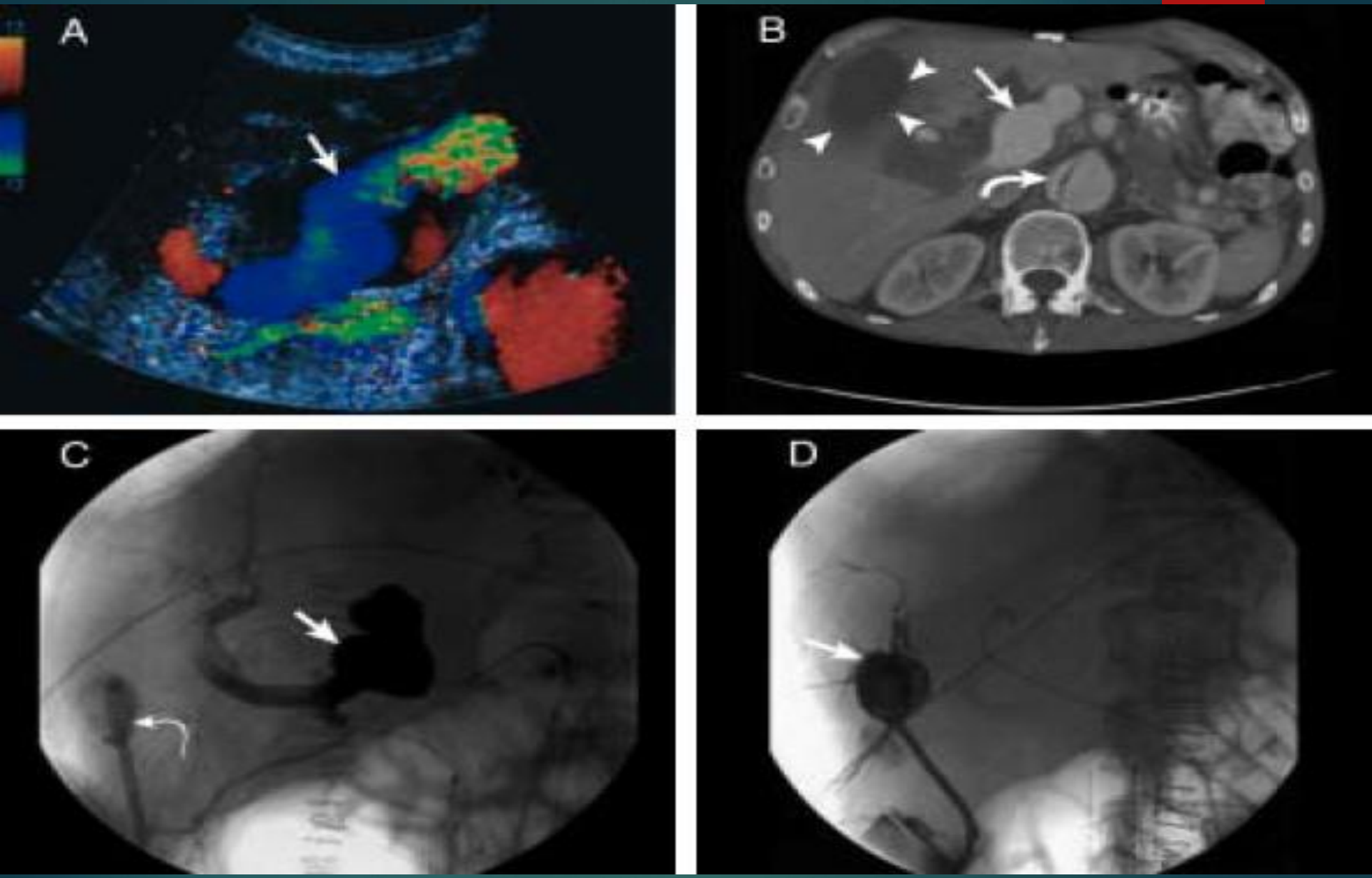

- C and D, Celiac arteriogram shows the common hepatic artery aneurysm (arrow) before (C) and after (D) embolization. Curved arrow (C) indicates a liver abscess being drained with a catheter.

Management

- **Intervention only** when the aneurysm is symptomatic or when risk factors for rupture (multiple aneurysms and a nonatherosclerotic etiology) are present.
- To prevent hepatic infarction, **ligation** of the affected artery or embolization of the aneurysm is best performed only if **the portal vein is patent.**
- Asymptomatic common hepatic artery aneurysms can be treated with **embolization or by ligation of the aneurysm without reconstruction**.
- **Vascular reconstruction** is required for the treatment of proper hepatic artery aneurysms to prevent hepatic ischemia resulting from interruption of collateral circulation through the gastroduodenal and right gastric arteries.
- Embolization of the hepatic artery or **stent-graft** placement may be used in patients at high surgical risk.

SMA Aneurysms

Etiology

Septic emboli , arteriosclerosis, polyarteritis nodosa, pancreatitis, biliary tract disease, neurofibromatosis, and trauma.

Clinical Manifestations

More than 90% abdominal pain and gastrointestinal bleeding. Acute mesenteric ischemia may result from thromboembolism of the artery.up to 50% of patients present with rupture, with a mortality rate of 30%. β-Adrenergic blockers may have a protective effect against rupture.

Management

- Ligation of an aneurysm of a branch of a mesenteric artery
- resection of any ischemic segment of bowel.
- Transcatheter embolization with a ruptured aneurysm.
- endovascular stent-graft .
- The use of β-adrenergic blockers can be considered for asymptomatic patients who are reluctant to undergo interventional procedures.

Thank you