

SACROSPINOUS FIXATION

JUNE 2019

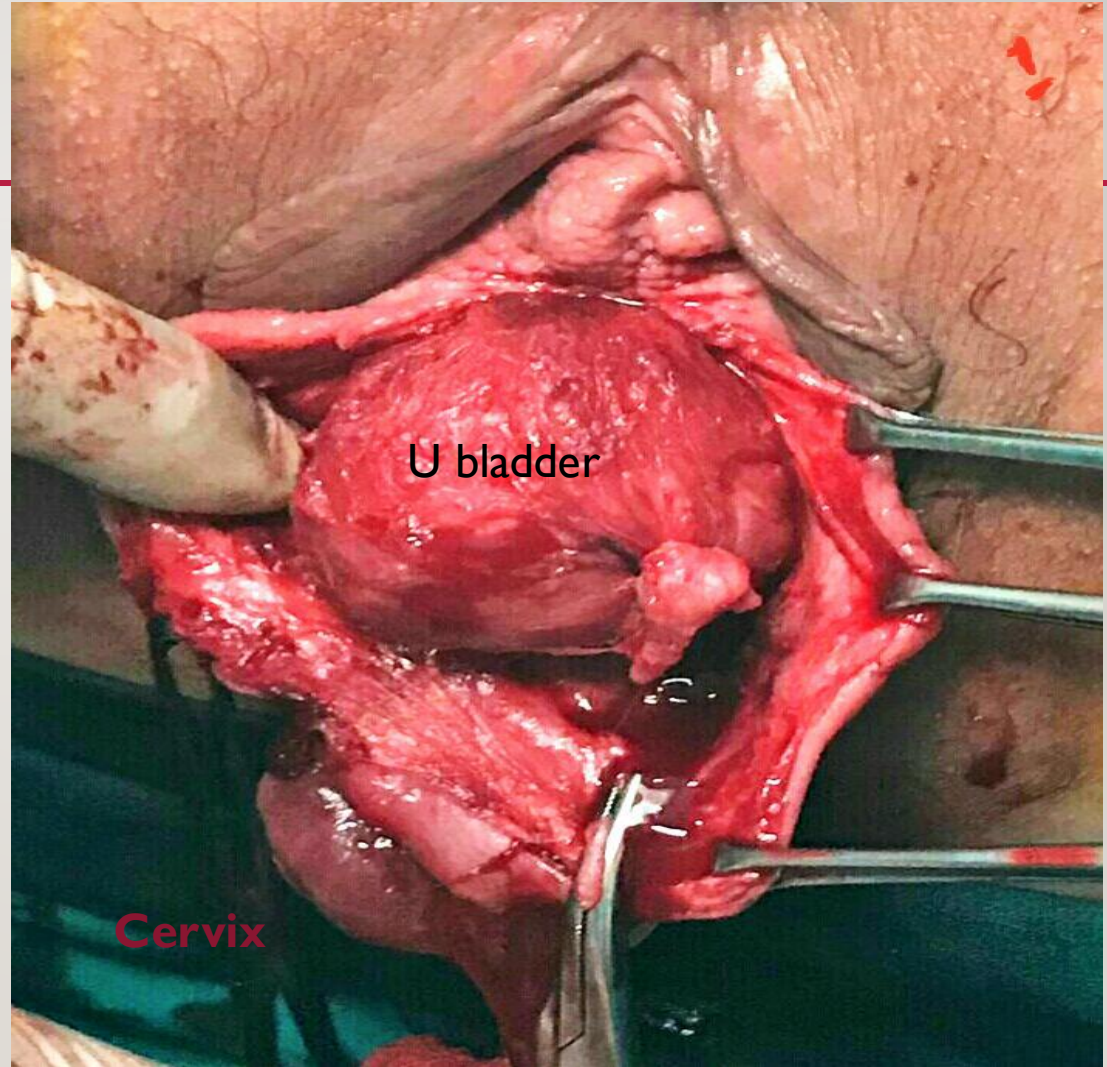
PREPARED BY: **RAFIK BARAKAT**

CASE SCENARIO

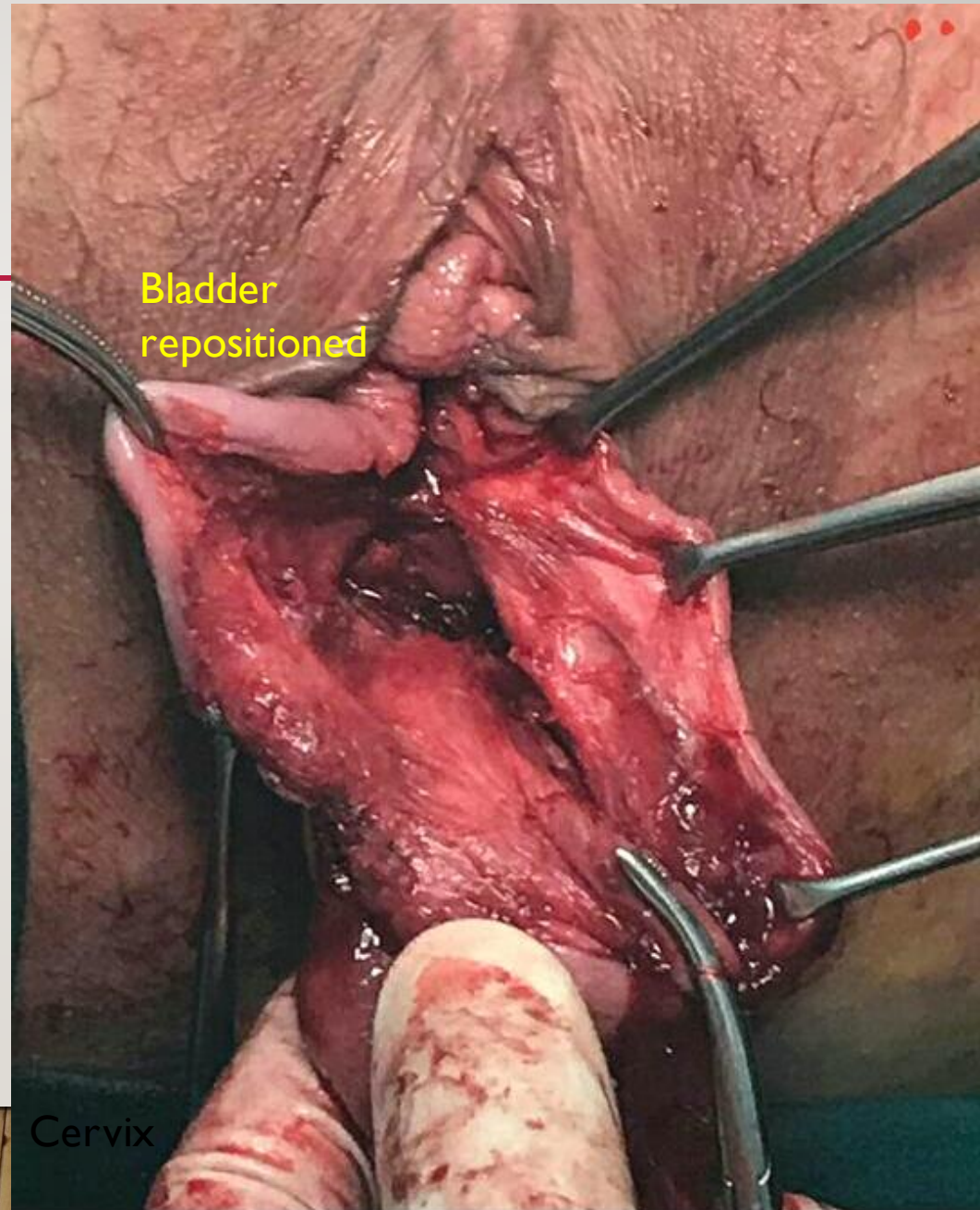
65 years old

- Subtotal hysterectomy
- Vault prolapse
- Cystocele
- Rectocele
- Enterocele sac

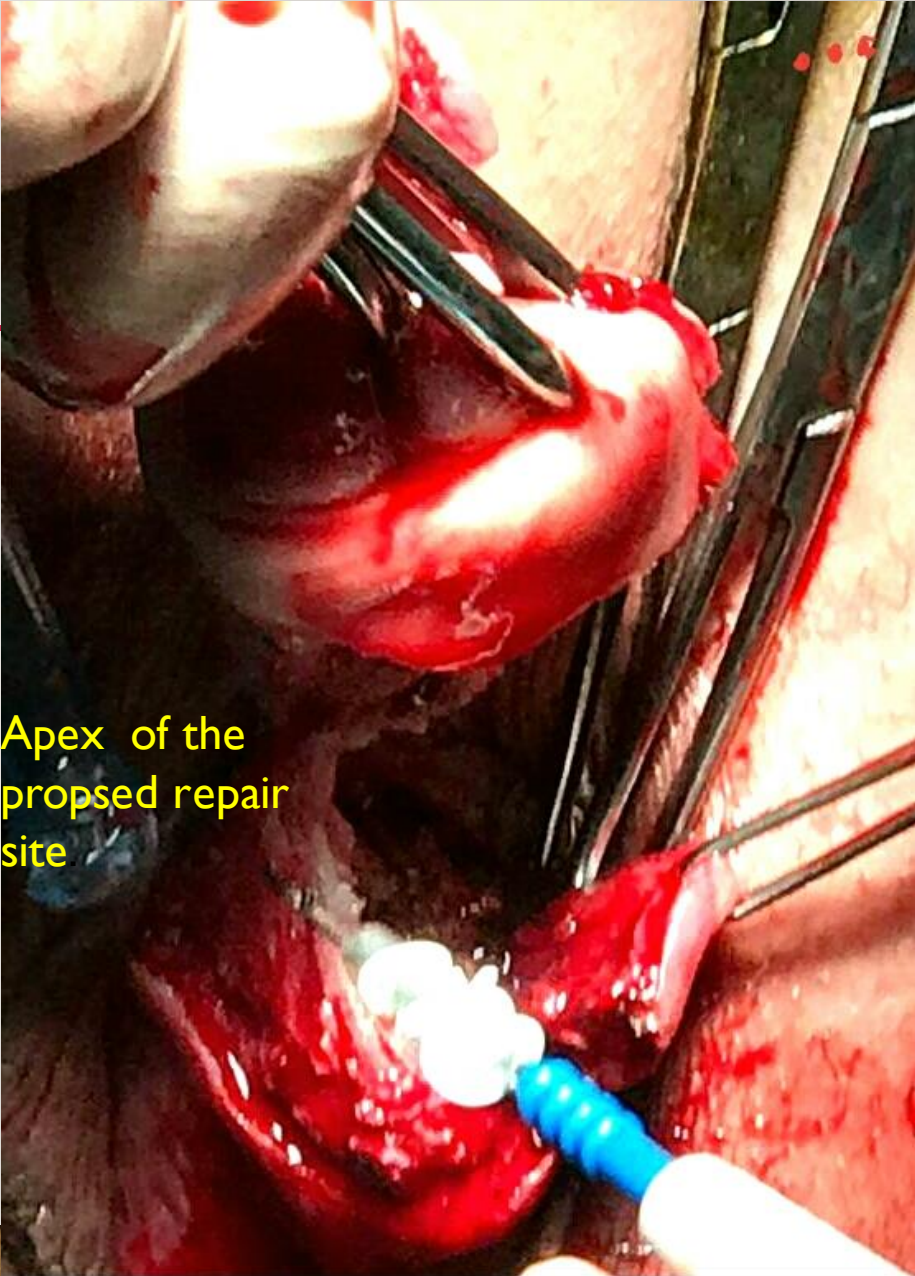
STEP :1
CORRECTOIN
OF CYSTOCELE



STEP :2
U.B .
REPOSITI
ONING
AND
FASCIAL
REPAIR

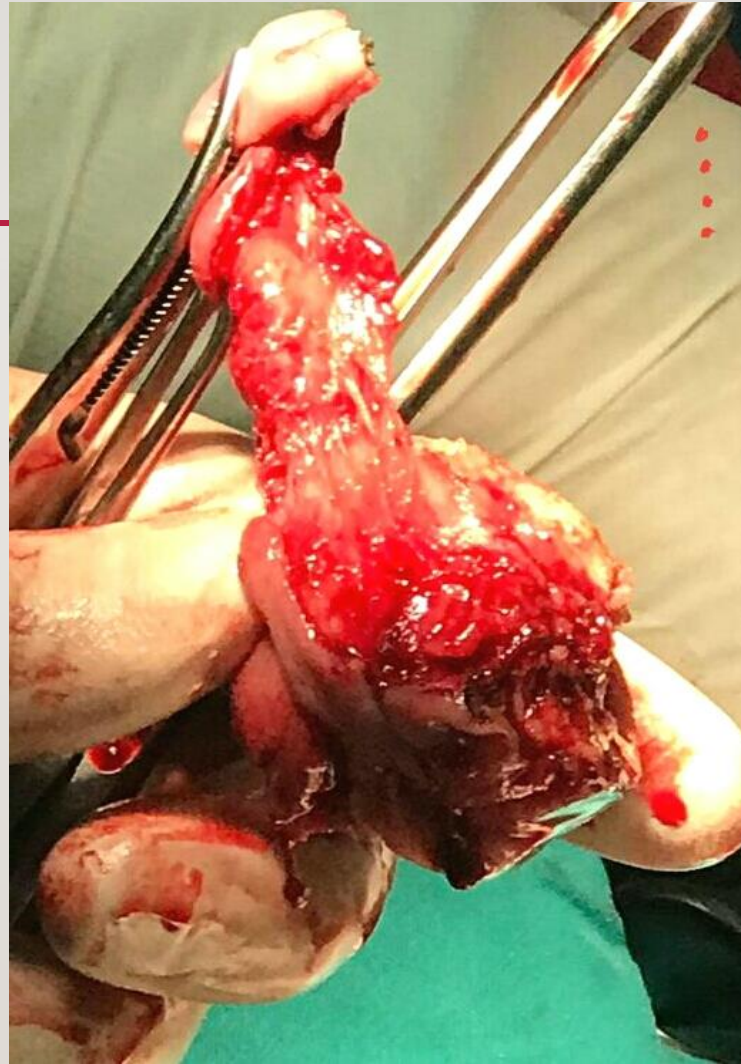

STEP YMOTCELEHCART:4

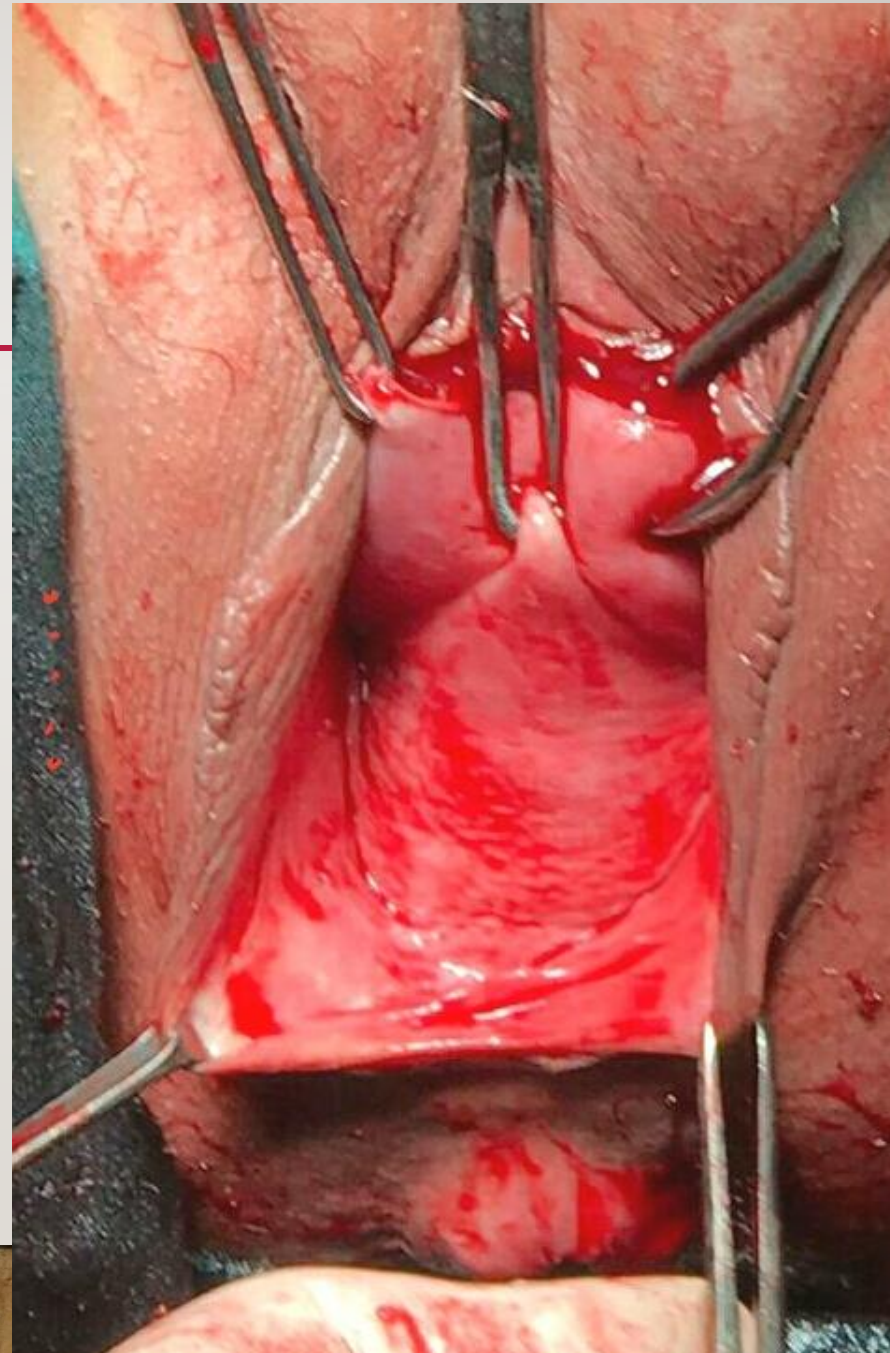


Apex of the
proposed repair
site

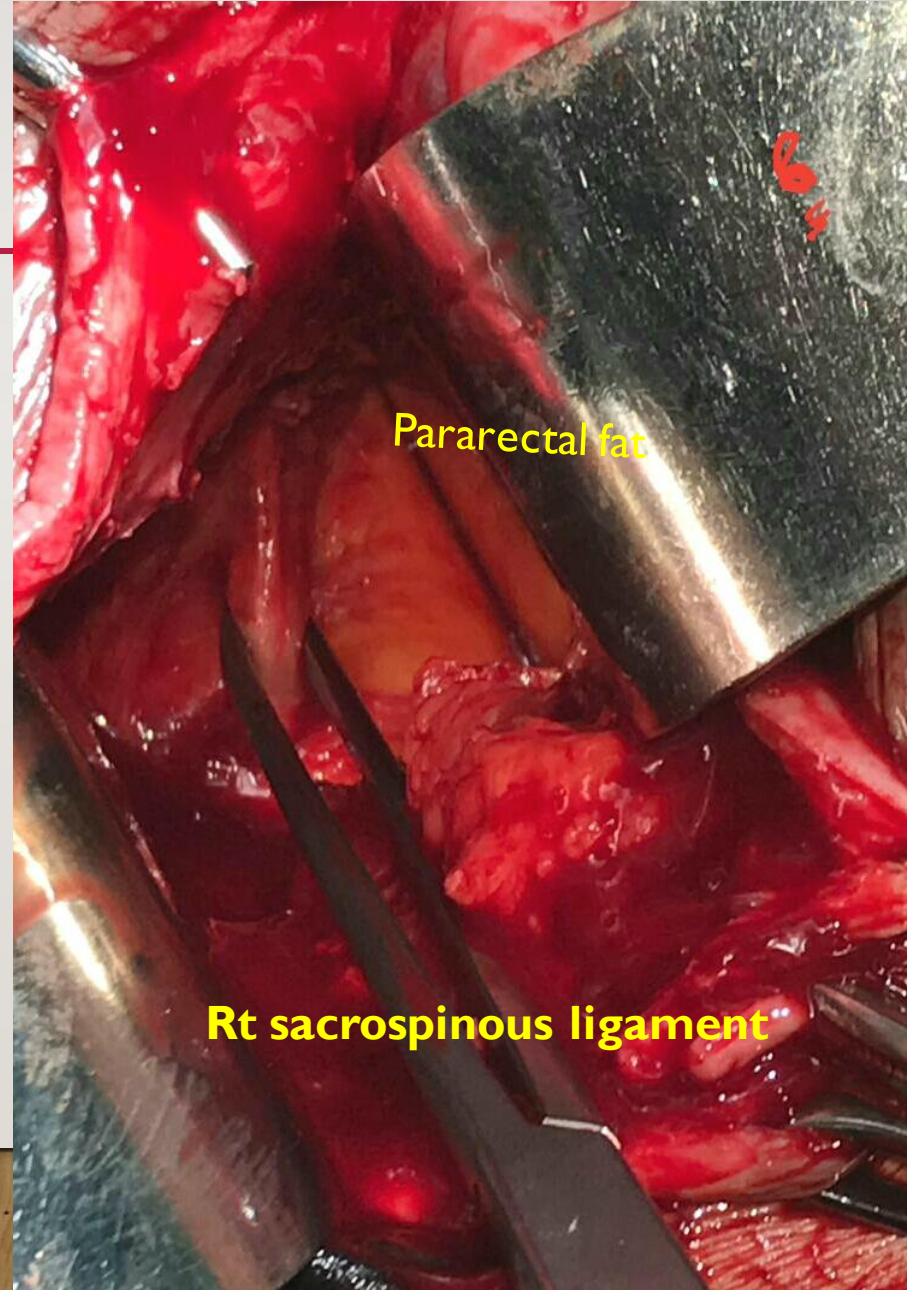
CERVIX



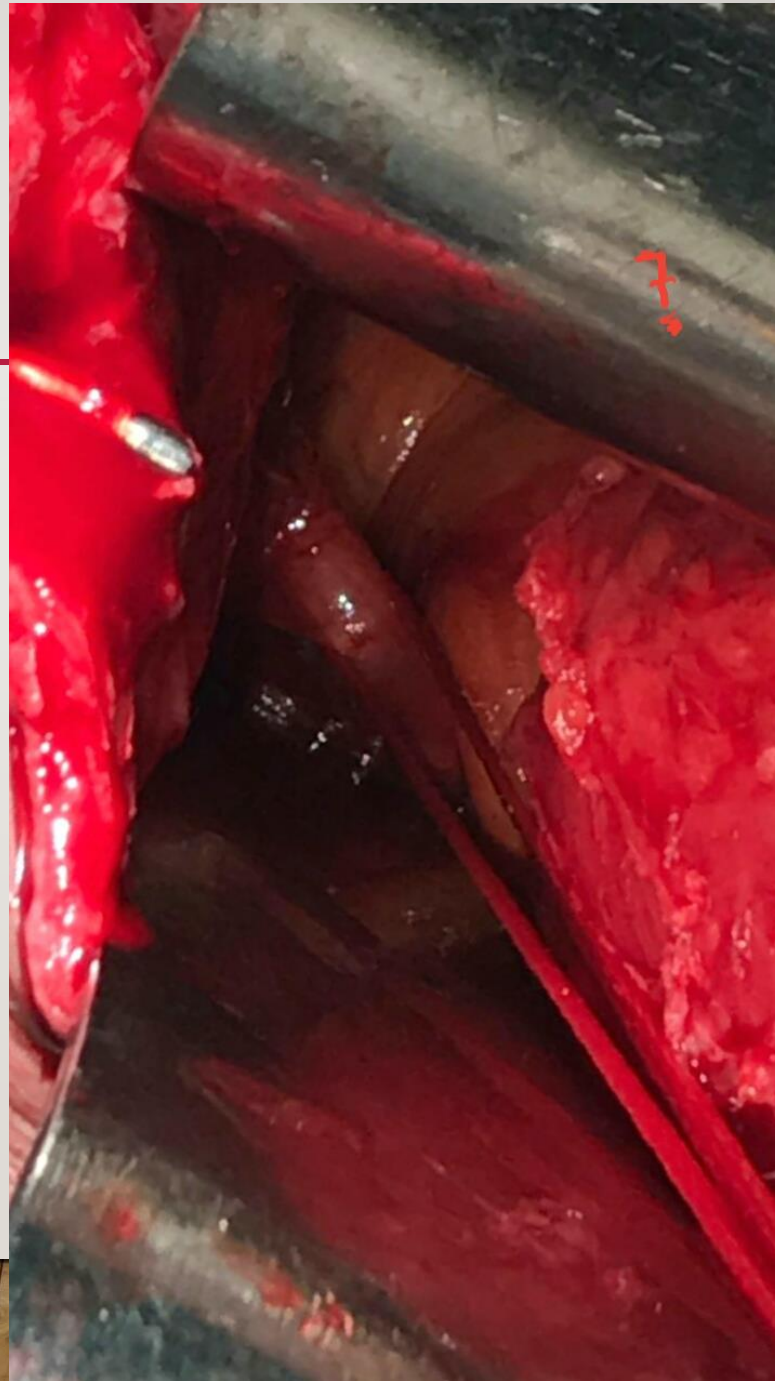
STEP :5
PREPARE
FOR
RECTOVAGINAL
DISSECTION



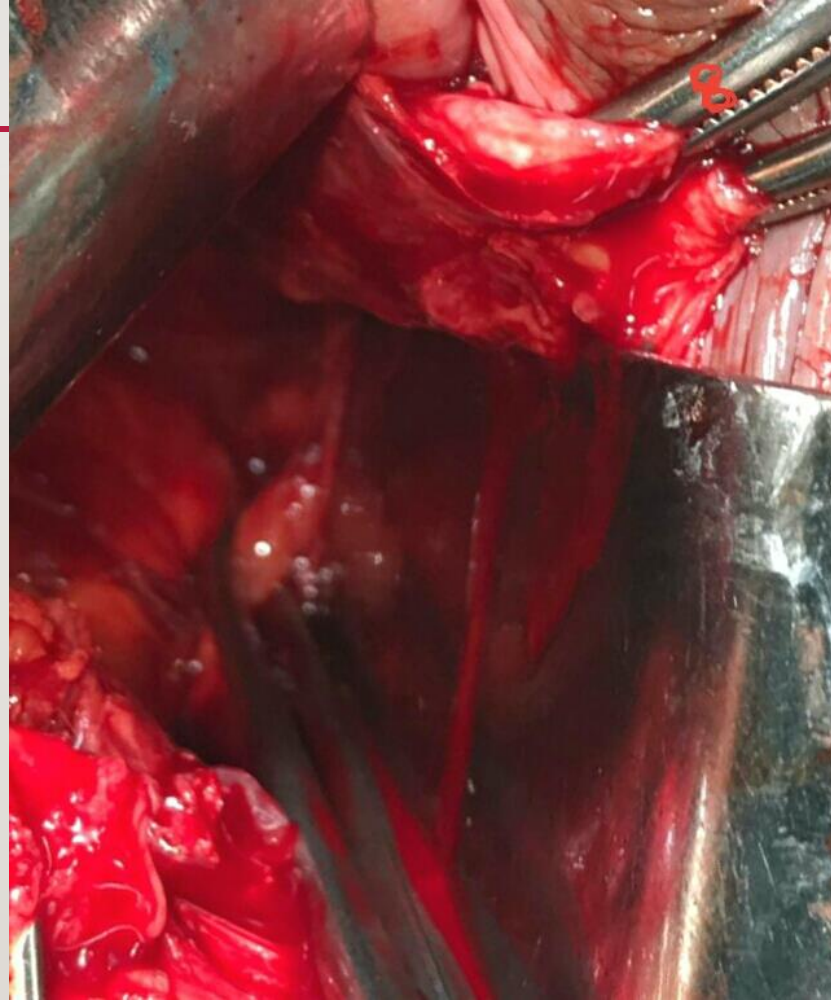
**STEP :6
RIGHT
PARARECTAL
SPACE
EXPOSURE**



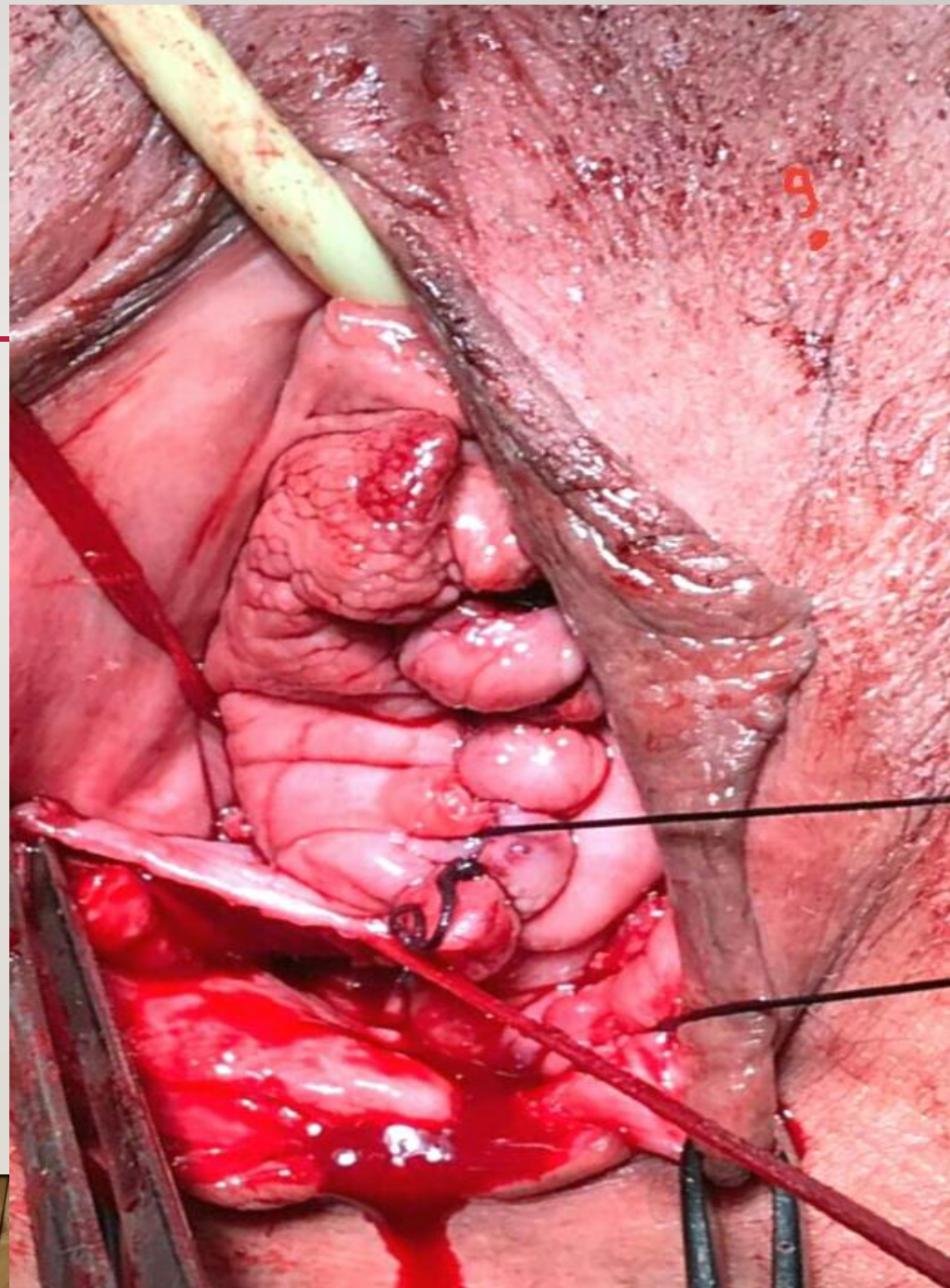
STEP :7
INSERTION
OF THE STITCH



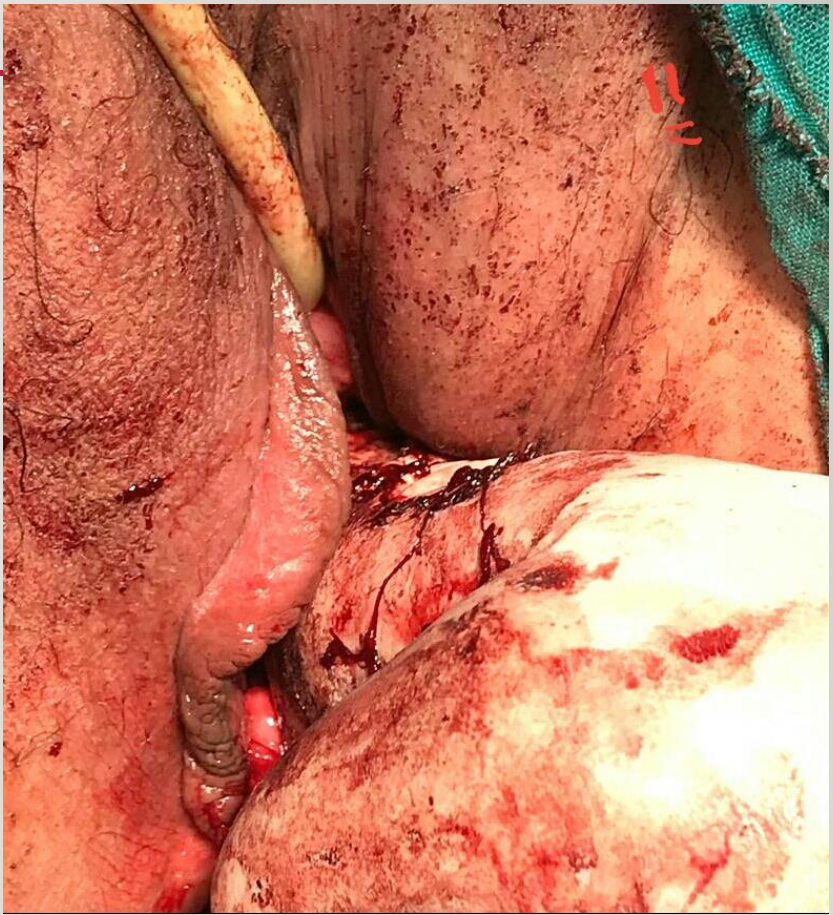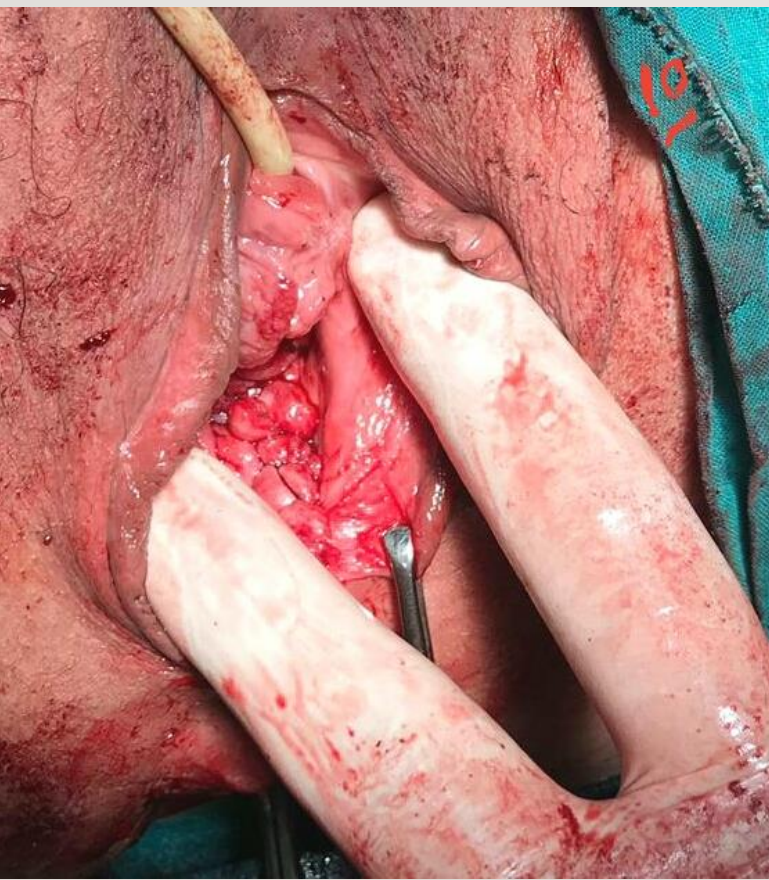STEP :8
LEFT SIDE



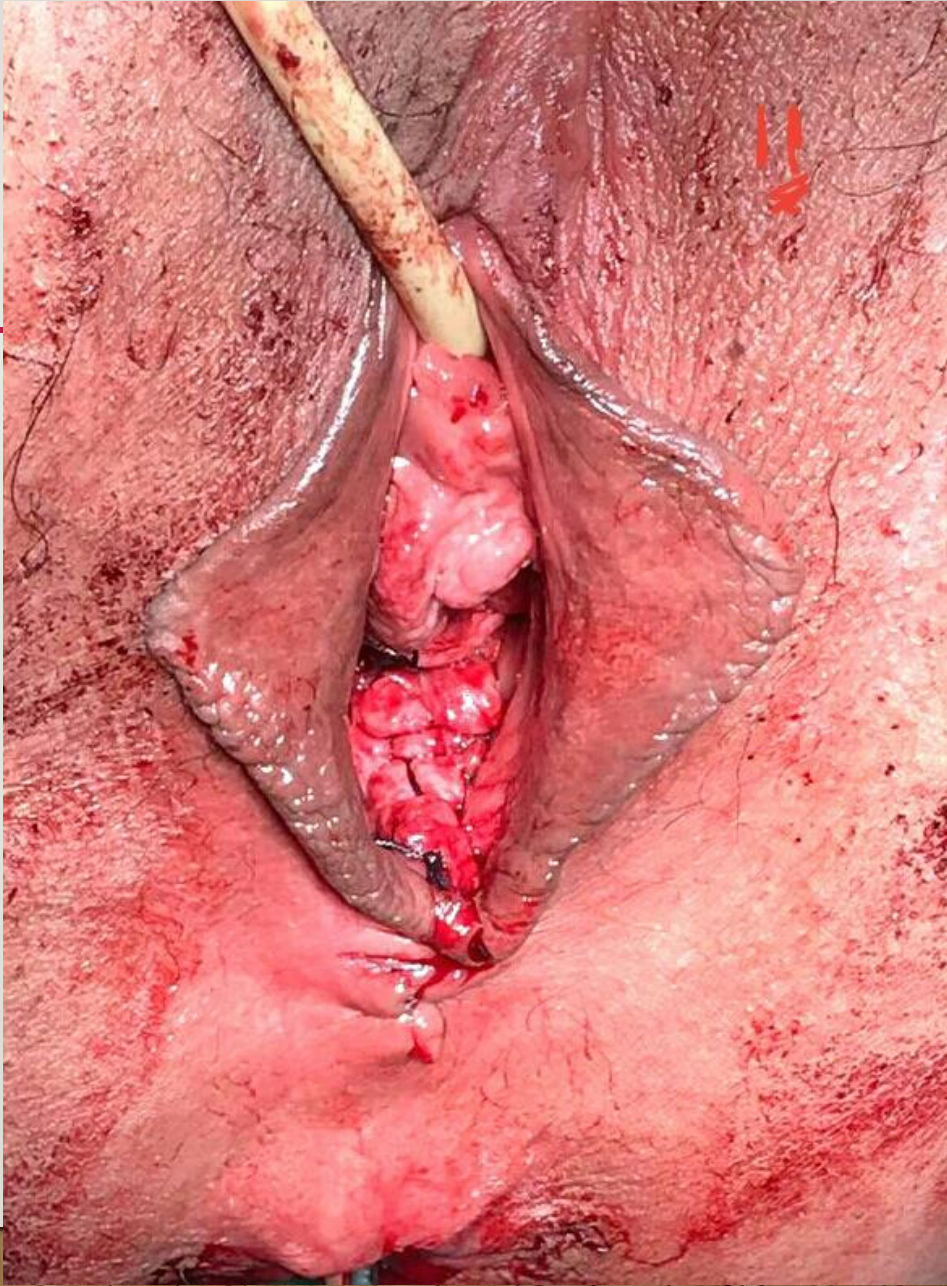
**STEP :9
FIXING
SACROSPINOUS
STITCHES TO THE
VAGINAL APEX
BILATERALLY**



STEP :10
ENSURING
VAGINAL
DEPTH
AFTER
COMLETE
CLOSURE



FINAL APPEARENCE



THANK YOU

- Rafik Barakat
- Ahmed Gibreel
- Ahmed Alameily
- Ali Nour